

Effect of a preceding laser dermabrasion on the outcome of combined therapy with narrowband ultraviolet B and potent topical steroids for treating nonsegmental vitiligo in resistant localizations

W. Bayoumi,* E. Fontas,† L. Sillard,* F. Le Duff,* J.-P. Ortonne,* P. Bahadoran,*‡ J.-P. Lacour* and T. Passeron*‡

Departments of *Dermatology and †Clinical Research, University Hospital of Nice, 06200 Nice, France

‡INSERM U895 Team 1, C3M, 06200 Nice, France

Summary

Correspondence

Thierry Passeron.

E-mail: passeron@unice.fr

Accepted for publication

29 July 2011

Funding sources

This study was supported by the 'Association Française du Vitiligo' and was promoted by the CHU of Nice, France.

Conflicts of interest

None declared.

DOI 10.1111/j.1365-2133.2011.10564.x

Background The treatment of vitiligo remains unsatisfactory.

Objectives To assess in patients with vitiligo the effect of a laser dermabrasion in addition to the association of topical steroids and ultraviolet (UV) B in difficult-to-treat areas.

Methods This was a single-centre prospective randomized trial including patients with nonsegmental vitiligo who had at least two symmetrical lesions located on bony prominences and/or extremities. An erbium laser-assisted dermabrasion was first performed on one side (randomly assigned). After 48 h, hydrocortisone 17-butyrate cream applied daily for three periods of 3 weeks followed by a 1-week steroid-free interval and narrowband UVB treatment was performed on both sides twice weekly for 12 weeks. The evaluation was performed on standardized pictures by two physicians blinded to the type of treatment received. The criterion of success was a repigmentation of at least 50%, 1 month after the end of the treatment.

Results Eighteen patients were included (24 paired lesions treated). Two patients dropped out for personal reasons. Almost 50% of lesions achieved at least 50% repigmentation in the dermabrasion side while only 4.2% did so with topical steroids and UVB alone ($P < 10^{-4}$). Side-effects were delayed healing, pain and two hypertrophic scars. The tolerance and patient satisfaction were 4/2 and 4/10 for the laser-treated side and 8/4 and 3/10 in the UVB+ steroids alone group, respectively.

Conclusions Laser dermabrasion significantly improves the repigmentation rate in vitiligo lesions. Despite a high rate of repigmentation in such difficult-to-treat areas the high rate of side-effects and the poor tolerance strongly limit its use in current practice.

The pathogenesis of vitiligo is poorly understood, although there is increasing evidence supporting the role of the immune system.^{1–3} Although they are crucial to induce repigmentation of the affected skin, the factors involved in the differentiation and proliferation of the melanocyte progenitors remain to be determined. Narrowband ultraviolet (UV) B (NB-UVB) and potent topical steroids are considered as the first-line treatment for generalized and localized vitiligo, respectively.^{4,5} Combination approaches with several sources of UV radiation and topical tacrolimus or pimecrolimus, or topical steroids, have improved the rate of repigmentation.^{6–8}

Despite this progress, extremities and bony prominences usually remain resistant to all current therapeutic approaches. The effect of preceding the NB-UVB with dermabrasion followed by topical application of 5-fluorouracil (5FU) was reported for treating nonsegmental vitiligo.⁹ This study raised interesting questions as 5FU is known to have little or no effect on melanocytic pigmentation and the role of dermabrasion by itself was not assessed. The objective of the study was to evaluate in patients with nonsegmental vitiligo the effect of a laser-assisted dermabrasion in addition to the association of topical steroids and UVB in difficult-to-treat areas.

Materials and methods

Setting, study design and patients

This was a single-centre study performed in the Department of Dermatology at the University Hospital of Nice, France. It was a prospective randomized controlled trial with intra-individual comparison and blinded evaluation. The study was approved by local ethical committee (Clinicaltrials.gov registration number: NCT01087216).

Twenty-five consecutive patients seeking treatment of their vitiligo were selected to enter the study. Seven did not meet the criteria and 18 were finally included in the study. Inclusion criteria were age 18–85 years, and nonsegmental vitiligo with at least two symmetrical patches of $> 4 \text{ cm}^2$ located on bony prominences and/or extremities. Exclusion criteria were pregnancy or lactation, personal history of skin cancer, personal history of photodermatitis, personal history of keloid or hypertrophic scar, and concomitant use of treatment potentially effective on vitiligo such as steroids or topical tacrolimus or pimecrolimus.

Intervention

After verification of the inclusion criteria and after patient consent was obtained one side of the body was randomly assigned to receive the laser-assisted dermabrasion. One hour after topical anaesthesia with prilocaine and lidocaine cream, dermabrasion was performed using a 2940-nm erbium laser (Burane[®]; Quantel, Les Ulis, France). The parameters were a fluence of 10 J cm^{-2} with a 5-mm diameter handpiece; in total three to 10 passages were performed until pinpoint bleeding was achieved. Simultaneously, and in order to reduce the pain, we directed pulsed cold air on the treated lesion

during the session. A daily dressing with hyaluronic acid cream (Ialuset[®]; Genévrier, Sophia-Antipolis, France) was applied for the first 2 days of treatment. Then, hydrocortisone 17-butyrate cream was applied daily on all lesions (dermabrasion treated or not) for three periods of 3 weeks followed by a 1-week steroid-free interval. Concomitantly NB-UVB was started on all the lesions with twice weekly sessions also for 12 weeks. The initial dose was 50 mJ cm^{-2} below the minimal erythema dose obtained on vitiligo skin. Doses were then increased by 50 mJ cm^{-2} every two sessions. If erythema lasting more than 48 h was observed, the doses were decreased to the highest doses that did not induce such a side-effect. Both sides received identical NB-UVB treatment.

Evaluation

Evaluation was done by two independent physicians blinded to the type of treatment received on standardized pictures (taken under visible light and UV radiation) performed before treatment and 1 month after the end of the treatment. An investigator's global assessment (IGA) was used with five grades of repigmentation (0, none; 1, $< 25\%$; 2, $25\text{--}49\%$; 3, $50\text{--}74\%$; 4, $\geq 75\%$). In case of discordance between the two evaluators a further assessment was made by a third physician. The criterion of success chosen was a repigmentation of at least 50% (IGA 3 or 4) at 1 month after the end of the treatment. Subjective evaluations of the tolerance and the global satisfaction of the patients were made on a visual analogue scale.

Statistical analysis

The statistical analysis was performed using a t-test and $P \leq 0.05$ was considered significant.

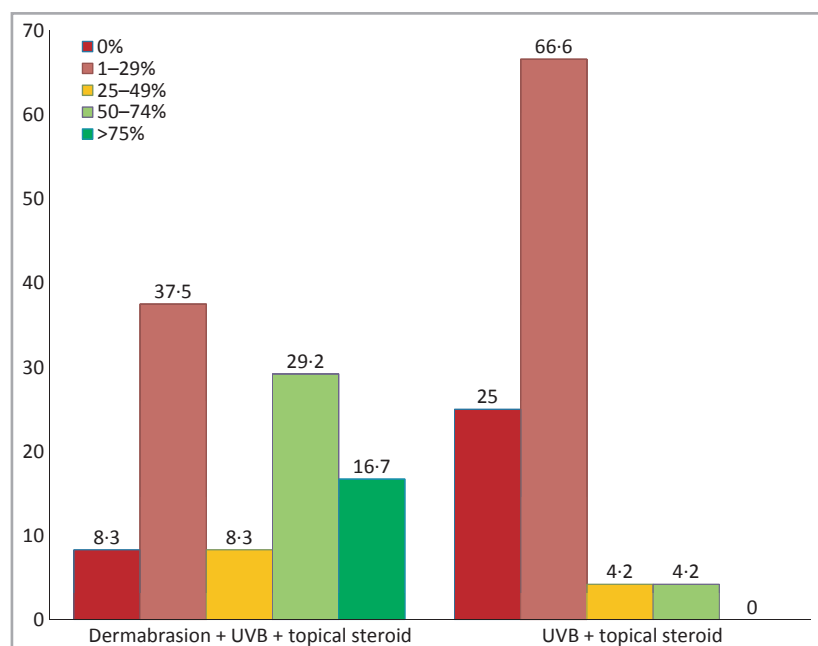


Fig 1. Repigmentation rate. UV, ultraviolet.

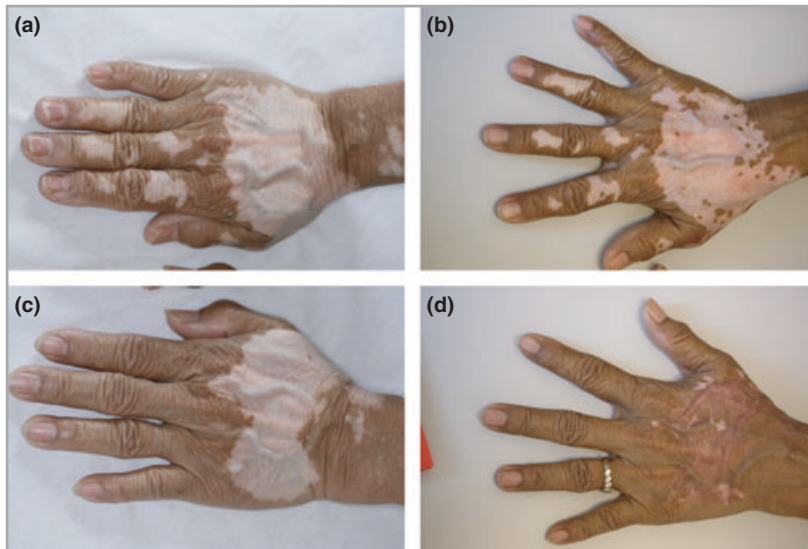

Fig 2. (a, b) Vitiligo lesions on the right hand before treatment (a) and 1 month after treatment with topical steroids and narrowband ultraviolet B (NB-UVB) (b). Note some repigmentation, but the result is not aesthetically satisfying. (c, d) Left hand before treatment (c) and 1 month after laser-assisted dermabrasion followed by topical steroids and NB-UVB (d). The repigmentation is almost complete but a hypertrophic scar has developed.

Results

Two patients dropped out for personal reasons. Sixteen patients (12 women and four men) were evaluated 1 month after the end of the treatment. The mean age was 49 years (range 29–72) and the skin types were II ($n = 7$), III ($n = 7$) and IV ($n = 2$). In total, 24 paired lesions were treated, 11 on the hands and feet and 13 on bony prominences (elbows, shoulders, knees and lower back). Almost 50% of the lesions treated with the laser-assisted dermabrasion achieved at least 50% repigmentation while only 4.2% did so with topical steroids and NB-UVB alone ($P < 10^{-4}$; Figs 1–3). Only the lesions treated with dermabrasion (16.7%) achieved complete or almost complete repigmentation. No lesion located at the extremities of the fingers achieved more than 50% repigmentation in any group. The pain level during treatment was high (mean 6.2/10, range 0–10). Side-effects were noted only in

the lesions treated with dermabrasion. We observed a delayed healing (up to 3 weeks in one patient), oedema lasting for 2–15 days when extremities were treated, and two hypertrophic scars (Fig. 2). The global tolerance was poorer on the dermabrasion side compared with topical steroids and NB-UVB alone: 4.2 and 8.4, respectively. The patients' global satisfaction was slightly better for the lesions treated with dermabrasion, without a statistical difference (4/10 vs. 3/10, $P = 0.15$).

Discussion

These results show that the laser-assisted dermabrasion significantly increases the rate of repigmentation when it precedes topical steroids associated with NB-UVB. The repigmentation rate with this approach appears relatively high if we considered that only classically resistant areas were treated. Indeed,

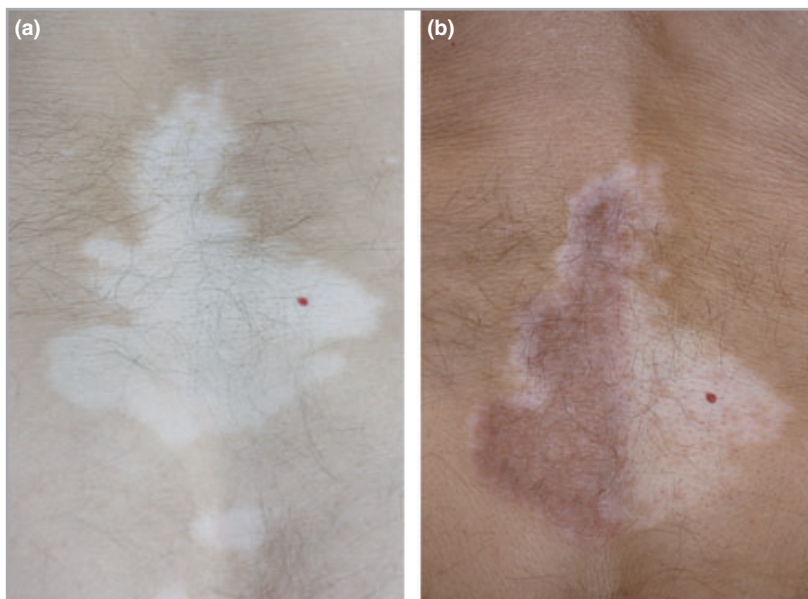


Fig 3. (a) Large vitiligo lesion on the lower back. (b) One month after treatment the repigmentation is almost complete on the left side treated with dermabrasion followed by topical steroids and narrowband ultraviolet B (NB-UVB) and is $< 25\%$ on the right side treated only with topical steroids and NB-UVB.

almost half of the lesions achieved at least 50% repigmentation and more than 16% achieved a complete or almost complete repigmentation. Data concerning the combined use of topical steroids and UV on resistant extrafacial vitiligo are limited. The poor rate of repigmentation achieved in our study with this association stresses the need for further studies to assess the true effect of such a combination in those areas compared with UV alone. The significant increase of pigmentation observed with dermabrasion raises interesting questions on the mechanisms involved in this process. Due to the dermabrasion, the previously laser-treated skin sites have received higher biological doses of UV radiation than the control sites. However, increasing only the UV doses does not appear to be able by itself to induce such an increase in the repigmentation rate. The penetration of the UV radiation was also increased by the dermabrasion, allowing a higher exposure of the dermis. Such a phenomenon could have a role and might have stimulated the melanocyte stem cells that have recently been demonstrated to be located in the dermis of glabrous skin.¹⁰ This higher biological UV impact due to the dermabrasion is one of the hypotheses that could explain the effect of dermabrasion in increasing the repigmentation in vitiligo. Removal of affected keratinocytes, increased penetration of the topical steroids and inducing inflammatory cytokines that might have a propigmenting action are other mechanisms that could have played a role.

The pain during the procedure and the healing process and the side-effects strongly impaired the tolerance and the global satisfaction of the patients. Interestingly, despite the high rate of repigmentation noted in the dermabrasion side compared with the side treated with topical steroids and NB-UVB without dermabrasion, the patients' final satisfaction was not significantly different between the two groups. Thus, the actual side-effects of such an approach strongly limit its use in current practice. However, further exploration of this issue may uncover the exact mechanisms of action of dermabrasion for repigmenting vitiligo and lead to new approaches in the near future.

What's already known about this topic?

- A preceding treatment with laser-assisted dermabrasion followed by 5-fluorouracil application was recently reported to improve the repigmentation rate induced by ultraviolet (UV) B treatment in vitiligo.

What does this study add?

- This study shows that dermabrasion followed by narrowband UVB and potent topical steroid treatment significantly improves the repigmentation rate in difficult-to-treat areas of vitiligo. However, the poor tolerance limits its use in current practice.
- Study of the mechanisms involved in the repigmentation induced by dermabrasion should provide interesting information.

References

- 1 Passeron T, Ortonne JP. Physiopathology and genetics of vitiligo. *J Autoimmun* 2005; **25** (Suppl.):63–8.
- 2 Jin Y, Birlea SA, Fain PR *et al.* Variant of TYR and autoimmunity susceptibility loci in generalized vitiligo. *N Engl J Med* 2010; **362**:1686–97.
- 3 Gregg RK, Nichols L, Chen Y *et al.* Mechanisms of spatial and temporal development of autoimmune vitiligo in tyrosinase-specific TCR transgenic mice. *J Immunol* 2010; **184**:1909–17.
- 4 Gawkrödger DJ, Ormerod AD, Shaw L *et al.* Guideline for the diagnosis and management of vitiligo. *Br J Dermatol* 2008; **159**:1051–76.
- 5 Whitton ME, Ashcroft DM, Gonzalez U. Therapeutic interventions for vitiligo. *J Am Acad Dermatol* 2008; **59**:713–17.
- 6 Passeron T, Ostovari N, Zakaria W *et al.* Topical tacrolimus and the 308-nm excimer laser: a synergistic combination for the treatment of vitiligo. *Arch Dermatol* 2004; **140**:1065–9.
- 7 Sassi F, Cazzaniga S, Tessari G *et al.* Randomized controlled trial comparing the effectiveness of 308-nm excimer laser alone or in combination with topical hydrocortisone 17-butyrate cream in the treatment of vitiligo of the face and neck. *Br J Dermatol* 2008; **159**:1186–91.
- 8 Esfandiarpour I, Ekhlesi A, Farajzadeh S *et al.* The efficacy of pimecrolimus 1% cream plus narrow-band ultraviolet B in the treatment of vitiligo: a double-blind, placebo-controlled clinical trial. *J Dermatolog Treat* 2009; **20**:14–18.
- 9 Anbar TS, Westerhof W, Abdel-Rahman AT *et al.* Effect of one session of ER:YAG laser ablation plus topical 5-fluorouracil on the outcome of short-term NB-UVB phototherapy in the treatment of non-segmental vitiligo: a left-right comparative study. *Photodermatol Photoimmunol Photomed* 2008; **24**:322–9.
- 10 Li L, Fukunaga-Kalabis M, Yu H *et al.* Human dermal stem cells differentiate into functional epidermal melanocytes. *J Cell Sci* 2010; **123**:853–60.